

Orthodontic Treatment of Malocclusion (Using the GEAW System)

Akiyoshi Shirasu and Sadao Sato

Research Institute of Occlusion Medicine, Kanagawa Dental University



Introduction

To establish a physiologic and functional occlusion, one must consider the principles of adaptation* and compensation*, make a precise diagnosis (strategy) based on the concept of malocclusion, and a well-defined treatment plan (tactics), and execute the tactics for achieving proper mandibular position, occlusal vertical dimension, occlusal plane inclination, occlusal guidance of each tooth, and stress management.

The Multiloop Edgewise Arch Wire (MEAW) appliance has traditionally been used as a tool to establish a functional occlusion. However, we have recently introduced a new treatment system with the use of orthodontic wire made of a new titanium alloy called GUMMETAL since its launch by Rocky Mountain Morita Corporation in June 2010 (Fig. 1). The titanium alloy combines superelasticity with superplasticity at room temperature without work hardening by wire bending. We have observed that the new orthodontic wire made of this unique alloy provides treatment results equivalent to those obtained with the MEAW appliance, without the

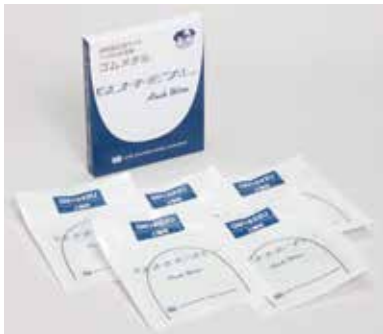

Fig 1. GUMMETAL orthodontic wires at the time of initial launch
GUMMETAL archwires were launched in June 2010.

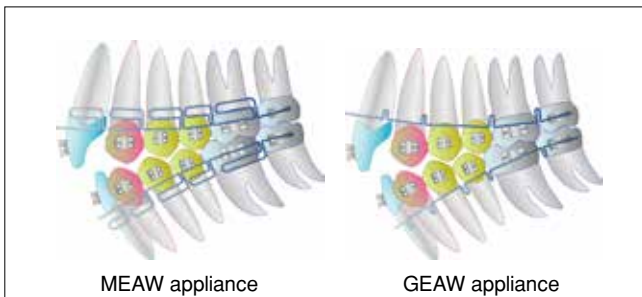


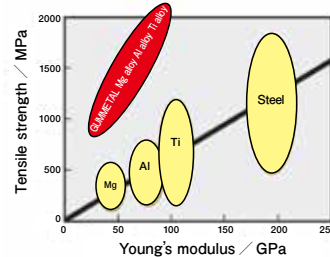
Fig 2. Schematic drawings of the MEAW and GEAW appliances

need for horizontal loops.

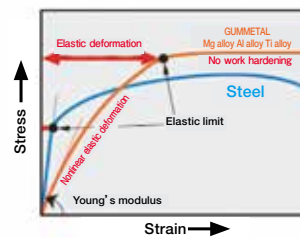
The orthodontic system in which GUMMETAL wires are utilized in place of the MEAW appliance based on the same orthodontic concept as the MEAW system is called the GUMMETAL Edgewise Arch Wire (GEAW) system. We have successfully achieved the goal of creating a functional occlusion using the GEAW system (Fig. 2).

However, neither the MEAW appliance nor the GEAW appliance would produce effective results if used only as a gear or gadget to move teeth. An individual's normal occlusion would be achieved only when the GEAW appliance is bent and adjusted based on proper diagnosis and treatment planning.

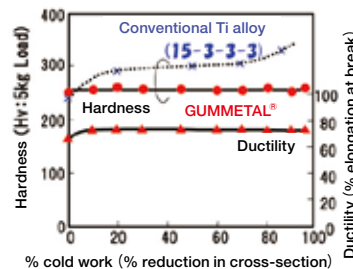
* GUMMETAL, a super elasto-plastic titanium alloy, has the following characteristics (Fig. 3)



1. The world's first alloy that combines ultra-low elastic modulus and ultra-high strength, which were regarded as incompatible in metals.



2. Superelasticity capable of enormous elastic deformation exceeding 2.5%, displaying nonlinear elastic deformation (making Hooke's Law invalid).



3. Superplasticity that permits cold working to 99.9% or more without work hardening.

Fig 3. Physical properties of GUMMETAL wire (Data courtesy of Toyotsu Mmaterial Incorporated)

* Adaptation is the process by which the body adjusts functionally to changes in the surrounding environment for life support (Fig. 4, Table 1).

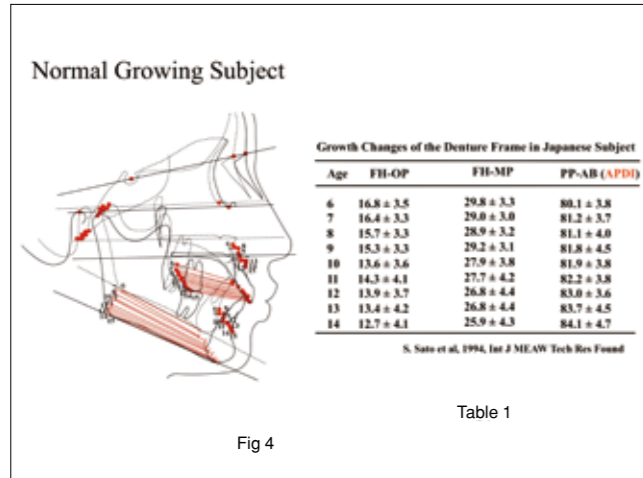


Fig 4

Fig 4. Table 1. The principle of adaptation in normal human maxillofacial growth. Maxillofacial growth, occlusal plane changes, and changes in anteroposterior dysplasia indicator (APDI) between age 6 and 14 years were studied. The occlusal plane angle (FH-OP) and mandibular plane angle (FH-MP) decreased with age. These changes were associated with increases in APDI (PP-AB). These findings suggest that in normal maxillofacial growth of modern man, the mandible rotates forward for occlusal adaptation and the mandibular plane angle decreases as the vertical dimension in the posterior dentition increases with age. The mandible assumes a more anterior position through this adaptation to gradually establish a Class I skeletal relationship.

How to bend and adjust the GEAW appliance

GEAW plier and bending of basic forms for the GEAW appliance

GEAW Plier is a loop-forming plier specially designed for GUMMETAL wire to achieve the objectives of the GEAW System (an orthodontic system aimed at establishing the functional occlusion proposed by Prof.



Fig 6. GEAW Plier
GEAW Plier was devised specifically for bending GUMMETAL wire to enable the GEAW system.

* Compensation is the process by which the body tries to maximize its function to make up for local structural defects (Fig. 5).

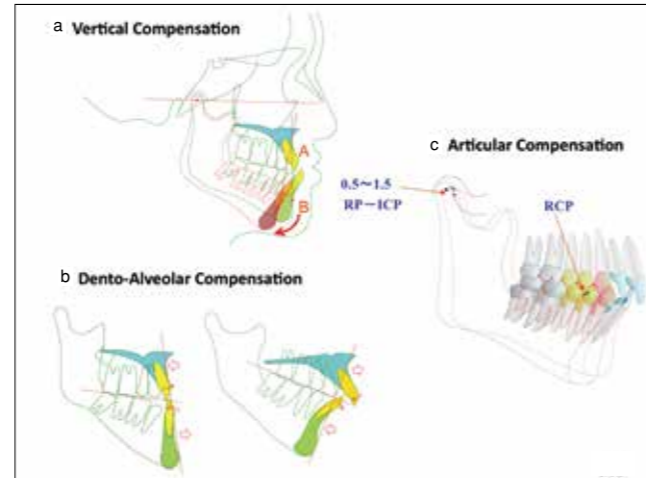


Fig 5. The body's compensatory responses. Compensatory responses of the body are designed to maximize function in response to local structural defects in the body. These include a) vertical compensation, b) dentoalveolar compensation, and c) articular compensation.

Sadao Sato using GUMMETAL wire)(Fig. 6, 7).

The two sides of each beak of the plier are perfectly rounded to a 1.3 mm diameter semicircle (0.65 mm radius) to allow bending of a loop on either side. The beak has a configuration of four-step pyramid. The top or first step is 2.5 mm in both width and height. A vertical loop formed using this step is called Short Form. The

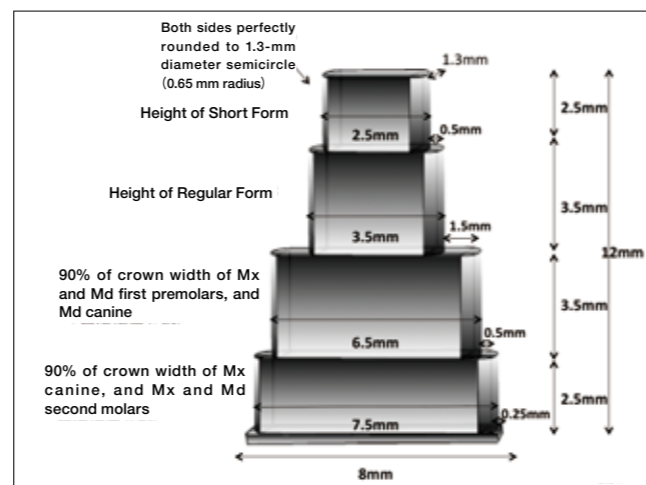


Fig 7. Schematic diagram showing the characteristics of GEAW Plier. The diagram illustrates the design specification of the plier.

second step is 3.5 mm wide and 3.5 mm high. A vertical loop formed on the second step is called Regular Form (Fig. 8). A vertical loop formed using the first and second steps is called Combination Form. Two types of Combination Form, step-up and step-down, can be made (Fig. 9). The third step is 3.5 mm in height, and 6.5 mm in width, approximately 90% of the average width of the maxillary and mandibular first premolars and mandibular canine. Likewise, the fourth step is 2.5 mm high, and 7.5 mm wide, approximately 90% of the average width of the maxillary canine and maxillary and mandibular second molars. The width of the base of the beak is 8 mm.

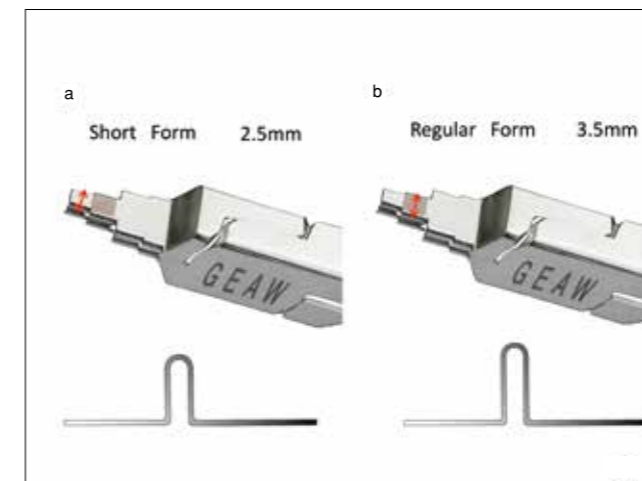


Fig 8. Configuration of Short Form and Regular Form
a. A vertical loop bent over the first step is called Short Form (2.5 mm).
b. A vertical loop bent over the second step is called Regular Form (3.5 mm).

The four steps are centered on the base, making the shelves equal in width on both sides of the beak: 0.5 mm for the first step, 1.5 mm for the second step, 0.5 mm for the third step, and 0.25 mm for the fourth step. Thus, the plier can also be used as a ruler for approximation of crown width.

Bending Procedures for Short, Regular, and Combination Forms

Short Form

Grasp GUMMETAL wire between the first steps of the beaks of the GEAW plier and bend a vertical loop 2.5 mm in height (equal to the width of the first step of the beak).

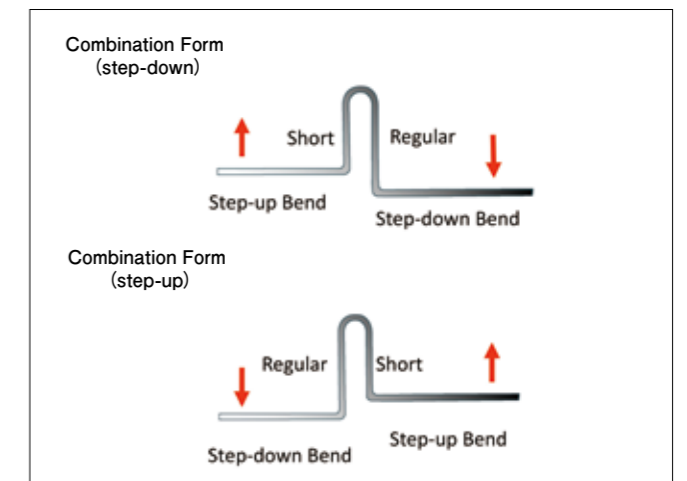


Fig 9. Configuration of Combination Form
A vertical loop bent with a combination of the first step (2.5 mm Short Form) and the second step (3.5 mm Regular Form) is called Combination Form. There are two types of Combination Form: step-up and step-down.




Fig 10. a-i: Short Form bending procedures
Grasp GUMMETAL wire between the first steps of the beaks to bend a vertical loop.

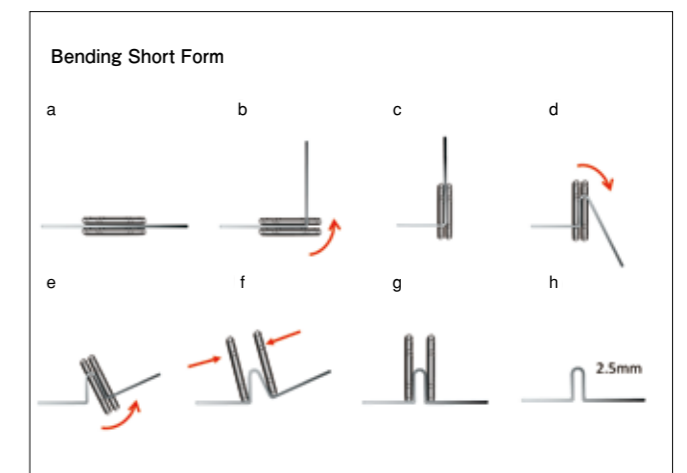


Fig 11. a-h: Diagram showing Short Form bending procedures

Regular Form

Grasp GUMMETAL wire between the second steps of the beaks of the GEAW plier and bend a vertical loop 3.5 mm in height (equal to the width of the second step of the beak).

Combination Form

Either type of Combination Form can be made using the first step (2.5 mm wide) and the second step (3.5 mm wide) of the beak.* For step-down Combination Form,

bend the first leg using the first step to the length of 2.5 mm, make a return bend, and bend the second leg using the second step to the length of 3.5 mm (Fig. 14, 15). For step-up Combination Form, bend the longer leg first using the second step (3.5 mm), followed by the shorter leg over the first step (2.5 mm)(Fig. 16, 17).

* Note: The terms, 'step-down' and 'step-up', are reversed for the mandibular arch.

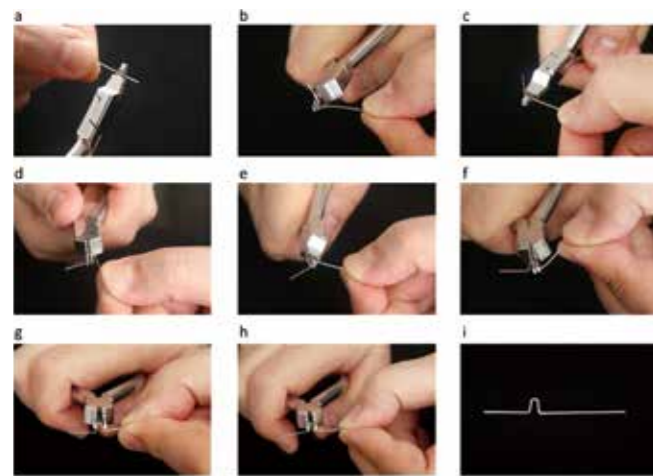


Fig 12. a-i: Regular Form bending procedures
Grasp GUMMETAL wire between the second steps of the beaks to bend a vertical loop.

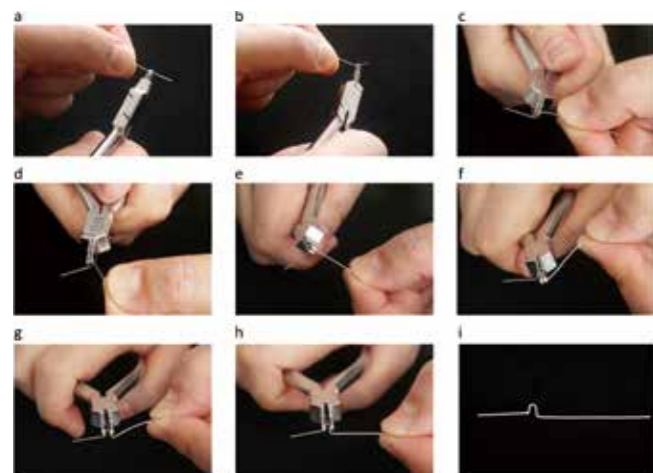


Fig 14. a-i: Combination Form (step-down) bending procedures
Grasp GUMMETAL wire between the first steps of the beaks for the first bend and then place the wire between the second steps of the beaks for a return bend to obtain a step-down bend.

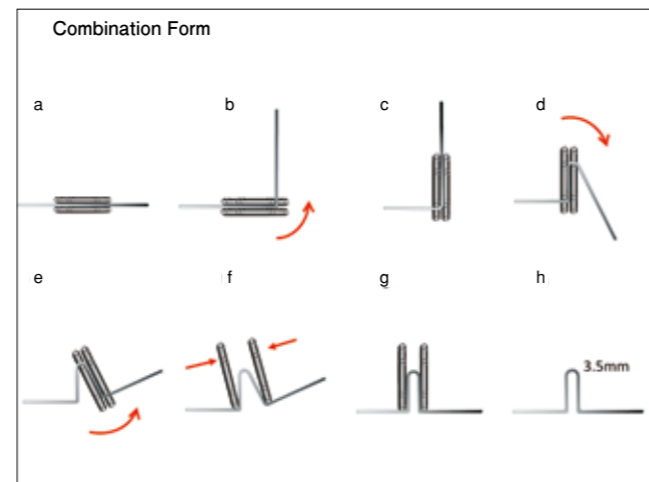


Fig 13. a-h: Diagram showing Regular Form bending procedures

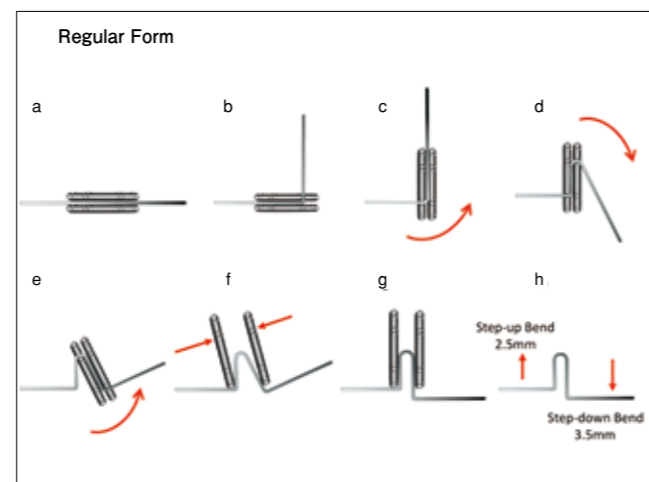


Fig 15. a-h: Diagram showing Combination Form (step-down) bending procedures

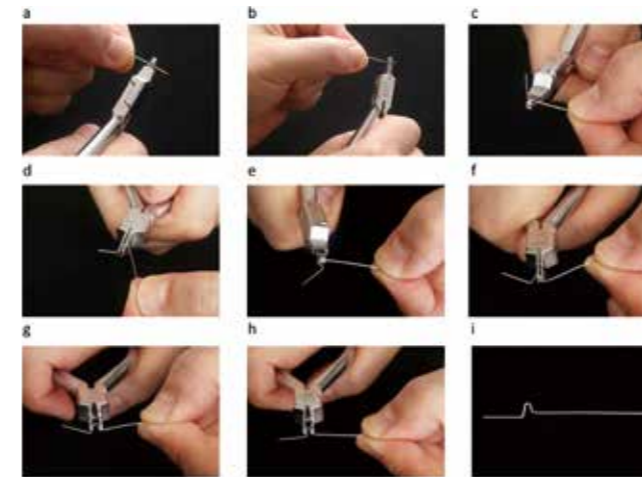


Fig 16. a-i: Combination Form (step-up) bending procedures
Grasp GUMMETAL wire between the second steps of the beaks for the first bend and then place the wire between the first steps for a return bend to obtain a step-up bend.

Maxillary and mandibular GEAW appliances

Rectangular 0.016×0.022, 0.017×0.022, and 0.018×0.022 inch GUMMETAL wires preformed to the maxillary and mandibular arch forms are main archwires used for the GEAW appliance (Fig. 18). Maxillary and mandibular GEAW appliances are fabricated by bending a combination of Short Form, Regular Form and Combination Form into

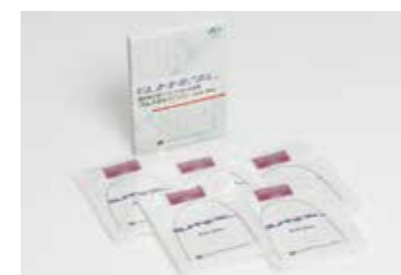

Fig 18. GUMMETAL wires
Wires used for the GEAW system.

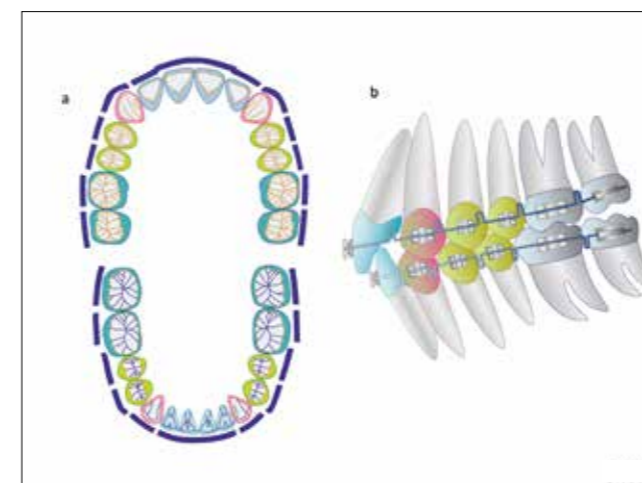


Fig 19. Schematic illustration of ideal arches for the GEAW system
a. occlusal views, b. lateral view of the ideal arches with vertical loops placed in the interproximal areas distal to the lateral incisors.

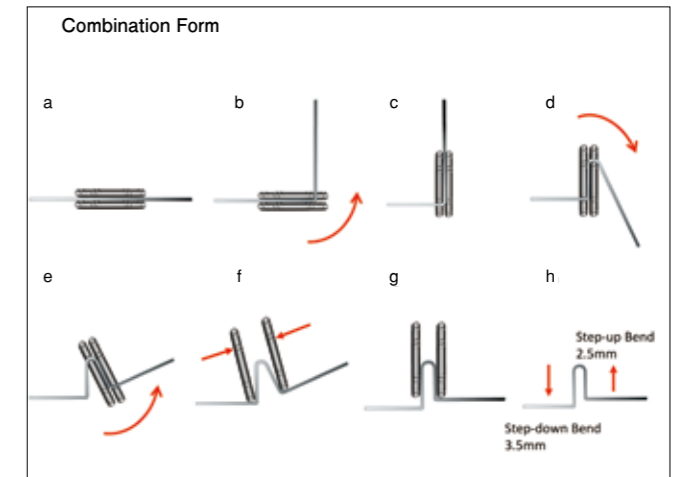


Fig 17. a-h: Diagram showing Combination Form (step-up) bending procedures

preformed archwires. Step bends designed to extrude the maxillary and mandibular premolars are incorporated into the archwire from the beginning of treatment. The GEAW appliance is essentially an ideal arch used at the final stage of edgewise treatment with first-order bends, tip-back bends for molars, and third order bends for torque control (Fig. 19). Completed maxillary and mandibular GEAW appliances are shown in Fig. 20.

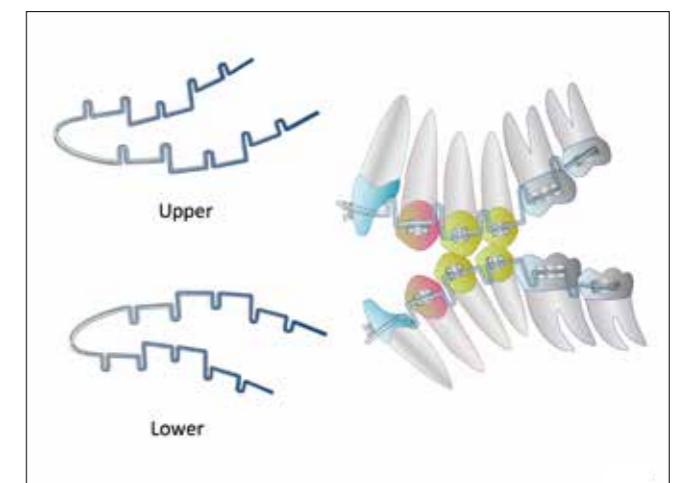


Fig 20. Schematic illustration of completed GEAW appliances
Unlike the MEAW appliance, step bends for premolars are incorporated into the GEAW appliance from the very beginning of treatment.

Mechanism of the GEAW appliance, clinical cases and adjustments according to skeletal pattern

Mechanism of the GEAW appliance

Treatment with the GEAW appliance is comprised of the same three basic mechanisms as with the MEAW appliance: 1) mesiodistal uprighting of teeth to improve the vertical dimension and the occlusal plane and gain mesiodistal space for the dentition (Fig. 21); 2) horizontal uprighting to correct mesial rotations of teeth, expand the arch, and gain horizontal space for the dentition (Fig. 22) ; 3) buccolingual uprighting of teeth to improve the vertical dimension and establish proper guidance and functional occlusion (Fig. 23). The GEAW appliance is

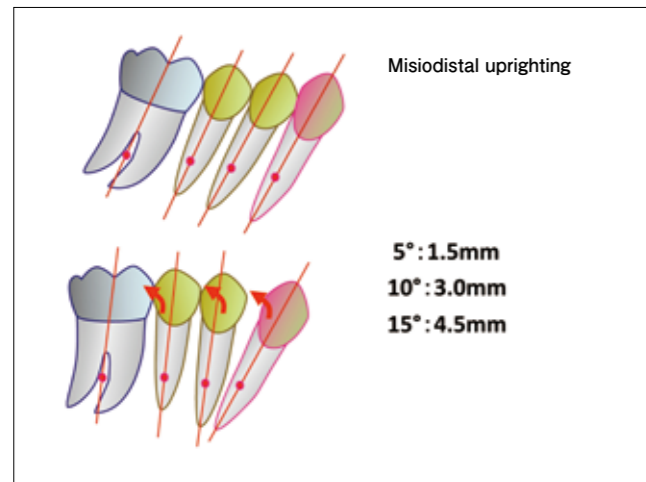


Fig 21. Mechanism of the GEAW appliance – 1

The GEAW appliance is able to upright teeth mesiodistally. Five degrees of uprighting creates 1.5 mm of space, and 10° and 15° of uprighting provide spaces of 3.0 mm and 4.5 mm (half the premolar width), respectively.

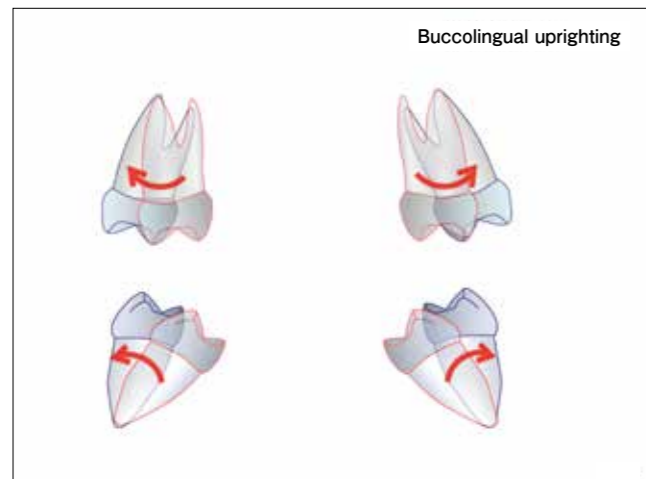


Fig 23. Mechanism of the GEAW appliance – 3

The GEAW appliance is capable of uprighting teeth buccolingually with the action of vertical loops and torque effect, allowing correction of the vertical dimension and arch expansion.

adjusted using these mechanisms.

The importance of the first premolar in occlusal reconstruction

Occlusal reconstruction around the first premolar as a key tooth is a very effective way to treat malocclusions with either the GEAW appliance or the MEAW appliance for the following reasons (Fig. 24). The first premolar is:

1. A pivotal posterior tooth in vertical control (susceptible to infraocclusion).
2. The fulcrum in occlusal plane reconstruction.
3. The most important posterior tooth, located in the center of the arch anteroposteriorly (lying midway

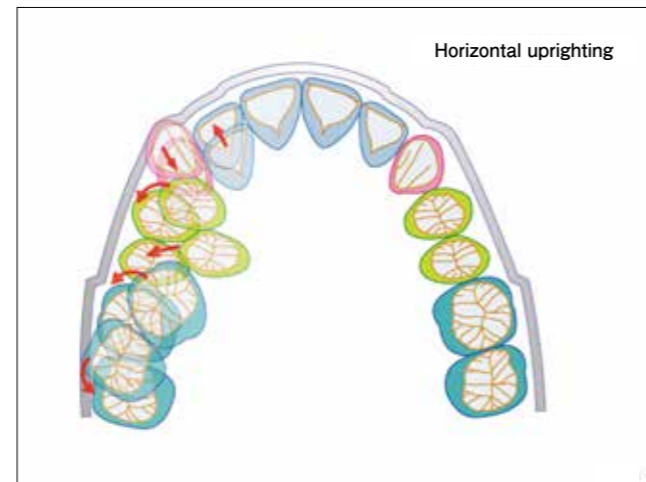


Fig 22. Mechanism of the GEAW appliance – 2

The GEAW appliance allows for effective lateral expansion of the arch with vertical loops incorporated into an ideal arch from the leveling stage. Teeth are uprighted in the horizontal plane with the action of vertical loops.

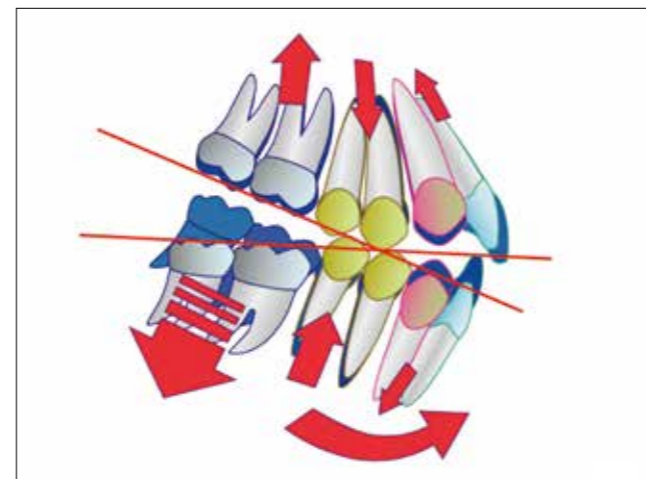


Fig 24. The importance of the first premolar in occlusal reconstruction

For effective use of the GEAW appliance, establishment of mandibular position through vertical height control in the premolar area is of utmost importance. Occlusal plane reconstruction around the premolars is key to successful correction of malocclusion.

between the posterior discrepancy and functional matrix and thus prone to occlusal discrepancy).

4. Less unaffected by masticatory muscle activities.
5. The most distant posterior tooth from the TMJ (effective for defining mandibular position).
6. A posterior tooth involved in retrusive guidance.

Thus, the first premolar plays a pivotal role in the reconstruction of the occlusal plane, necessitating the incorporation of step bends into the premolar area of the GEAW appliance from the very beginning of treatment.

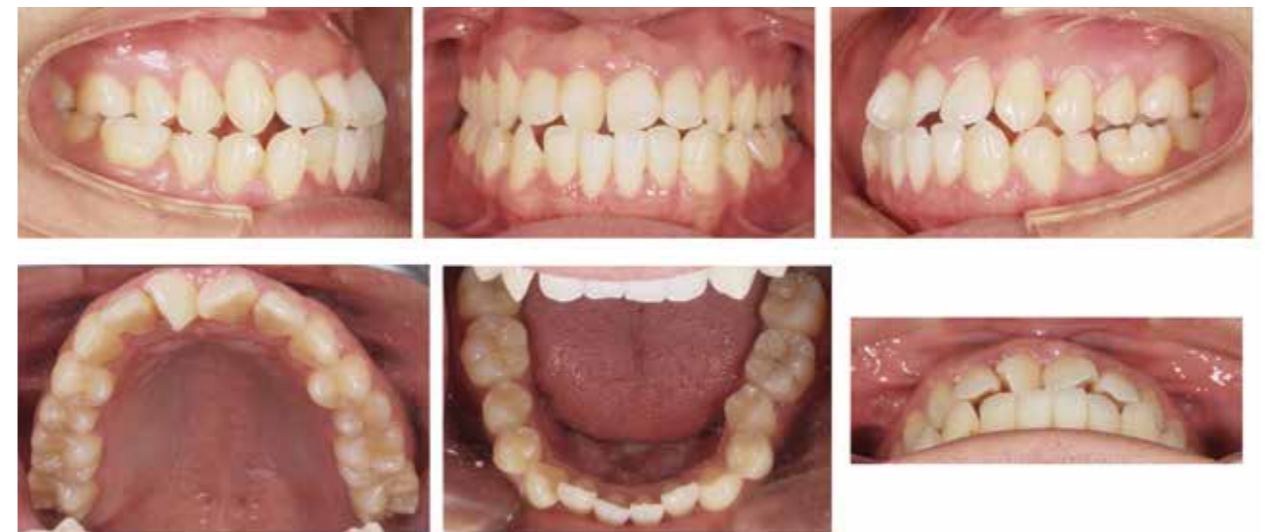

Fig 25. Initial intraoral photographs of a high-vertical Class III open-bite case

The canine and molar relationships were Angle Class III with an anterior open bite and anterior crowding.

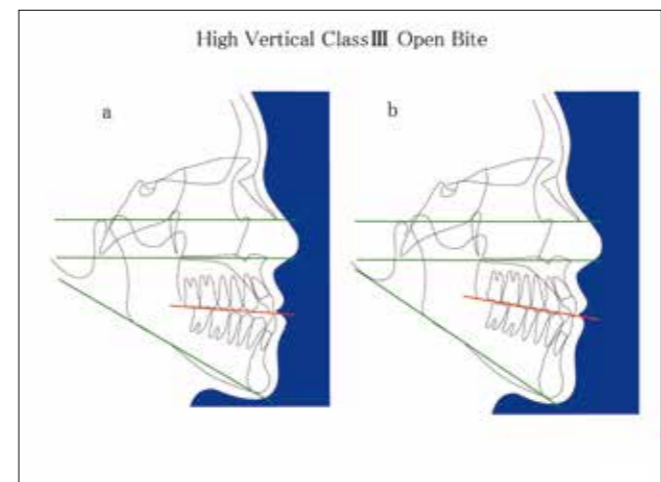


Fig 26. Pretreatment and prediction tracings: a, pre-treatment morphological characteristics; b, treatment objectives

Clinical cases and adjustments of the GEAW appliance according to skeletal pattern

The GEAW appliance is adjusted basically in the same manner as the MEAW appliance. Because treatment goals vary depending on the type of malocclusion, adjustments of the appliance must be individualized for each patient.

(1) Sequence of high-vertical Class III open-bite treatment

A male patient presented with an anterior crossbite and anterior crowding. Intraoral examination revealed a Class III canine and molar relationship, an overjet of 1.0 mm

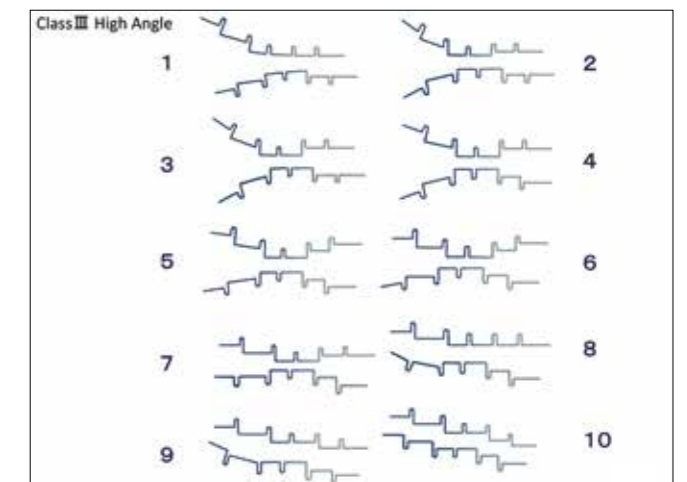


Fig 27. Sequence of high-vertical Class III open-bite treatment with the GEAW appliance

This malocclusion with severe posterior discrepancy requires intrusion and uprighting of maxillary molars with heavier tip-back bends, establishment of mandibular position with step-up bends in the premolar area, and steepening of the flat occlusal plane for occlusal reconstruction. Steps 1 through 10 illustrate the sequence of high-vertical Class III open-bite treatment.

and overbite of -1.0 mm, crowding and an open bite (Fig. 25). The treatment goals were to correct, through an occlusal approach, the maxillofacial skeletal disharmony responsible for the morphological characteristics of this malocclusion, restore mandibular function, and achieve dynamic harmony of the maxillofacial skeleton. To attain these goals, it was necessary to eliminate the posterior discrepancy, a contributing factor to this malocclusion, decrease the vertical dimension in the maxillary posterior area, and steepen the flat occlusal plane due to overerupted maxillary molars (Fig. 26). The following

bends were required to accomplish necessary tooth movements: tip-back bends in the molar area and step bends in the premolar area to eliminate interferences, followed by step-down bends in the anterior area and step-up bends in the posterior area to steepen the flat occlusal plane by rotating it around the premolar area and tipping it up in the back (Fig. 27). Intraoral progress photographs are shown in Fig. 28 and posttreatment photographs in Fig. 29.

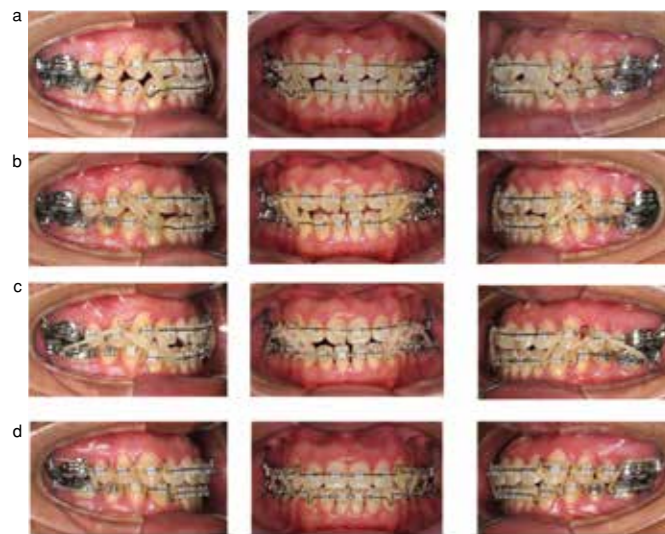

Fig 28. Treatment progress

- One week after the start of treatment with 0.016×0.022 inch GEAW appliances with step bends incorporated in the premolar area from the very beginning of treatment and tip-back bends in the molar area. Vertical elastics were attached to Kobayashi hooks mesial to the canines except for the mandibular right canine where a Kobayashi hook was replaced with a crimpable hook.
- At 3 months, 0.017×0.022 inch GEAW appliances were placed with increased tip-back bends in the molar area. The step bends in the maxillary and mandibular premolar areas were also increased. Step bends were added to the mandibular anterior area to raise the vertical dimension. Vertical elastics and short Class III elastics (3/16 inch, 6 oz.) were attached to Kobayashi hooks and loops mesial to the maxillary and mandibular canines.
- At 5 months, posterior interferences were eliminated, allowing the mandible to move distally. The tip-back bends in the molar area were decreased to initiate occlusal plane reconstruction. Kobayashi hooks were placed mesial to the maxillary canines and first premolars and distal to the mandibular lateral incisors for use of vertical elastics and short Class III elastics. Kobayashi hooks were placed distal to the mandibular first premolars as well to start posterior rotation of the mandible with Class III Check elastics (3/16 inch, 6 oz.).
- At 10 months, step-up bends were incorporated into the mandibular molar area and step-down bends into the maxillary anterior area to steepen the occlusal plane (stepped up in the back). Triangular elastics and box form elastics (3/16 inch, 6 oz.) were worn in the anterior and posterior areas to obtain solid intercuspation.

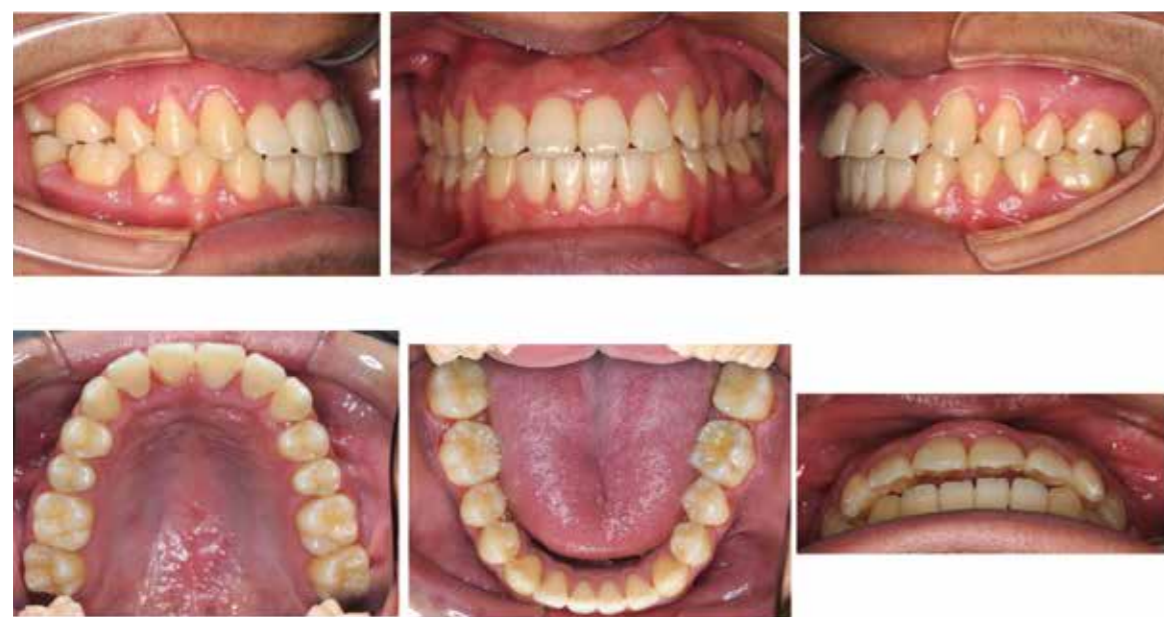

Fig 29. Posttreatment intraoral photographs
Angle Class I canine and molar relationships were achieved, and anterior crowding was eliminated.

(2) Sequence of low-vertical Class III deep-bite treatment

The patient was an adult female with the chief complaint of an anterior crossbite and a labially displaced maxillary right canine. Intraoral examination revealed an Angle Class I molar relationship, an Angle Class III canine relationship on the right side with a labially displaced maxillary right canine, deviation of the mandibular dental midline to the left by half the tooth width, and an overjet of -2.1 mm and overbite of 2.1 mm (Fig. 30). Treatment was aimed at changing the lower facial height with a vertical height increase mainly in the premolar area, flattening the steep occlusal plane in the

maxillary molar area, and controlling excessive functional rotation of the mandible (Fig. 31). Step-down bends for the maxillary premolar area and step-up bends for the mandibular premolar area were needed to increase the vertical dimension and inhibit excessive anterior rotation of the mandible due to active ramus growth exceeding the amount of increase in the occlusal vertical dimension. Step-down bends were added to the maxillary molar area to flatten the occlusal plane (Fig. 32). Treatment progress (Fig. 33) and posttreatment intraoral photographs (Fig. 34) are shown below.

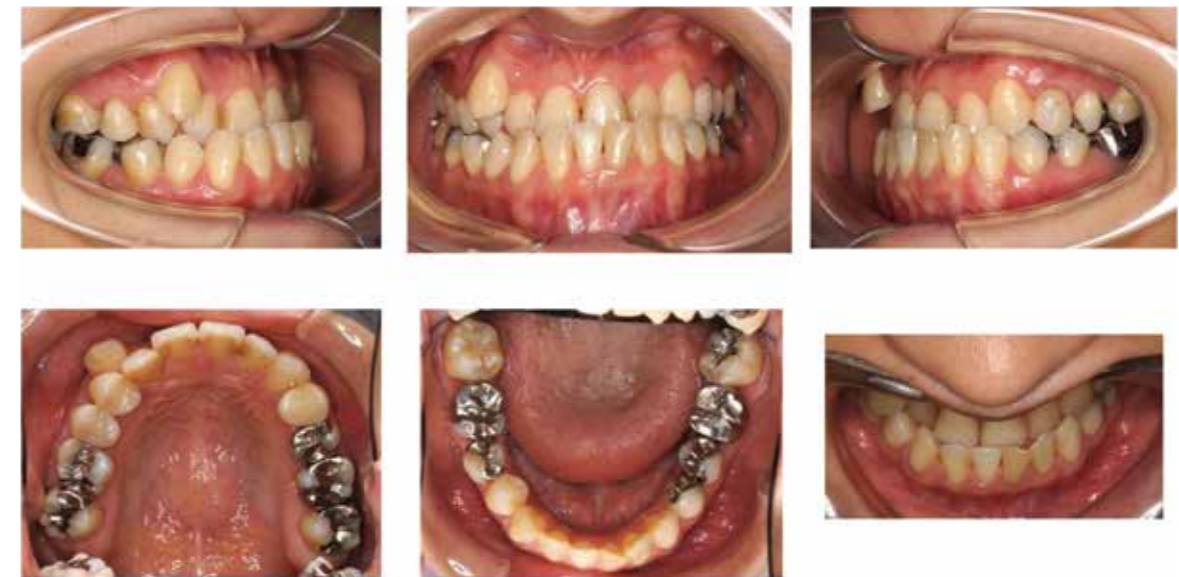

Fig. 30 Initial intraoral photographs of a low-vertical Class III deep-bite case
The molar relationship was Angle Class I, while the canines were in Angle Class III relationship on the right side with the lower dental midline deviated to the left by half the tooth width.

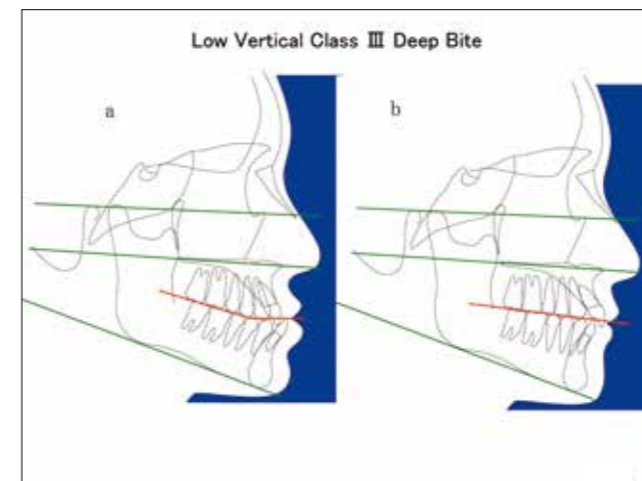


Fig. 31 Pretreatment and prediction tracings: a, pretreatment morphological characteristics; b, treatment objectives

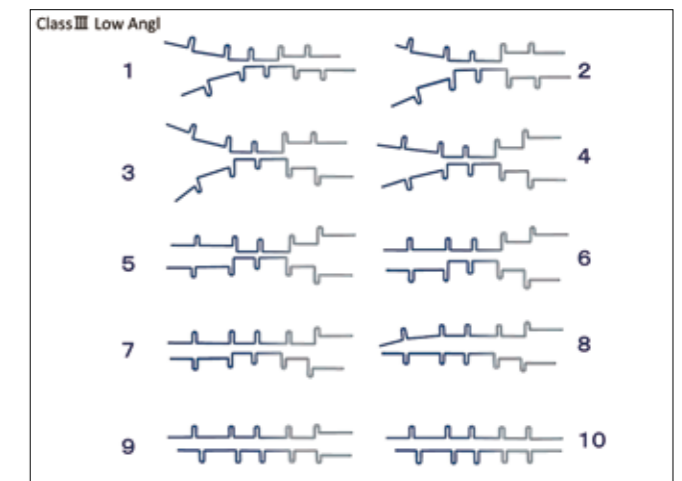
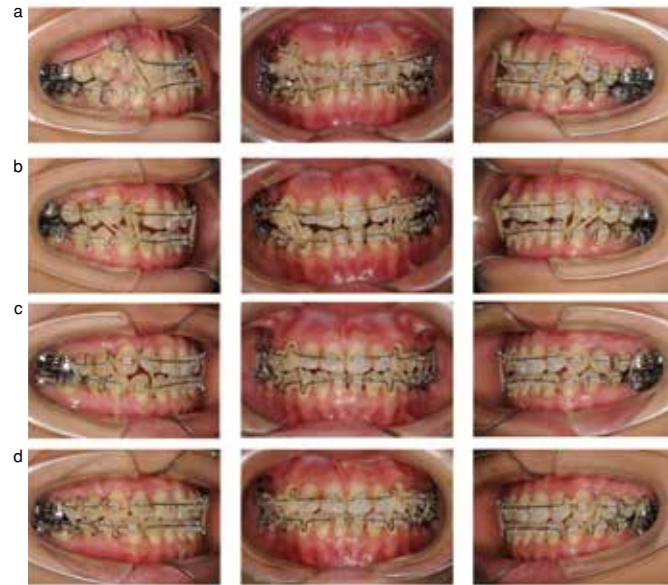

Fig. 32 Sequence of low-vertical Class III deep-bite treatment
This malocclusion was caused by excessive mandibular rotation due to a lack of occlusal vertical dimension. Occlusal reconstruction thus required flattening of the occlusal plane with step-up bends in the premolar area to increase the vertical dimension. Bends were made following the steps 1 through 10.



- One month after the start of treatment with 0.018×0.022 inch maxillary left MOGW and maxillary right GEAW appliances, and a 0.016×0.022 inch mandibular GEAW appliance. Vertical and horizontal leveling was initiated with step bends in the premolar area and a series of 25° tip-back bends in the molar area from the very beginning. Vertical elastics (3/16 inch, 6 oz.) were used.
- At 3 months, the initial appliances were changed to 0.017×0.022 inch GEAW appliances in both arches with increased step and tip-back bends in the premolar and molar areas, respectively. Step bends were given to the mandibular anterior area to ensure anterior coupling. Vertical elastics and short Class III elastics (3/16 inch, 6 oz.) were used.
- At 7 months, the maxillary molars were extruded with step-down bends. The patient wore a vertical-pull box elastic in the right anterior area, a Class II -pull box elastic in the left anterior area, and vertical-pull box elastics in the posterior area.
- At 12 months, all bends except step-down bends in the molar area and a step bend in the mandibular left anterior area were removed for tooth axis control and establishment of occlusal guidance. Vertical-pull box elastics were used in the anterior and posterior areas.

Fig. 33 Treatment progress

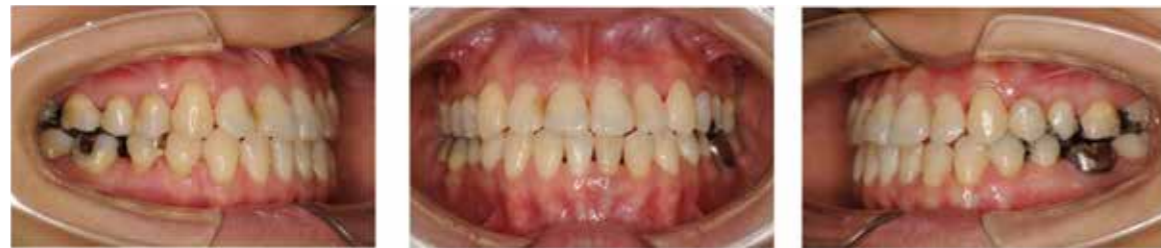

Fig. 34 Posttreatment intraoral photographs
Both the molar and canine relationships became Angle Class I, and midline deviation was corrected.

(3) Sequence of low-vertical Class II open-bite treatment

An adult female patient presented with an anterior open bite. Initial intraoral findings include Angle Class I canine and molar relationships, an overjet of 4.9 mm and overbite of -2.9 mm, and mild crowding in the maxillary and mandibular anterior areas (Fig. 35). Her malocclusion was characterized by an extremely steep occlusal plane in the molar area,

leading to an increased mandibular plane angle, distally driven mandibular position, and increased susceptibility to temporomandibular disorder. Her abnormally low vertical dimension of the maxillary dentition was making mandibular forward adaptation difficult. It was therefore necessary to flatten the occlusal plane by actively increasing the vertical dimension of the maxillary molar area for restoration of

functional mandibular movement (Fig. 36). Maxillary adaptation in a direction opposite to that of a high-vertical Class III open-bite malocclusion had led to anterior rotation of the maxilla with growth. Step-up bends were made in the mandibular premolar area to increase the vertical dimension. Because the occlusal plane in the molar area was steep, the mandibular molars were uprighted and intruded with tip-back

bends and step-down bends, respectively. Furthermore, the maxillary molars were extruded with step-down bends to increase the vertical dimension and tip the occlusal plane down in the back, so that the mandible would rotate anteriorly to obtain a functional occlusion (Fig. 37).

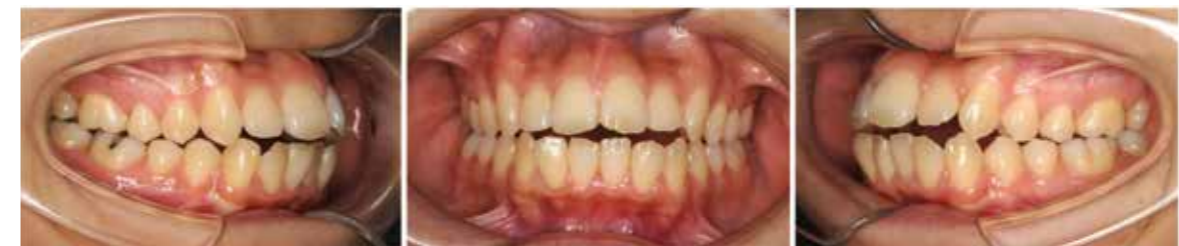

Fig. 35 Initial intraoral photographs of a low-vertical Class II open-bite case
The canine and molar relationships were Angle Class I with an anterior open bite and mild crowding of the maxillary and mandibular anterior teeth.

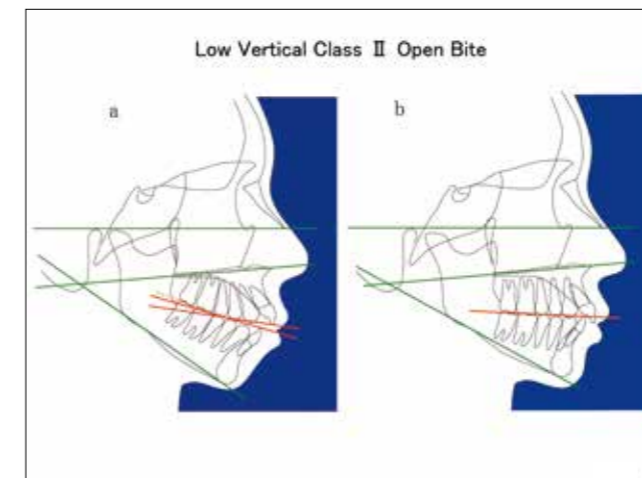
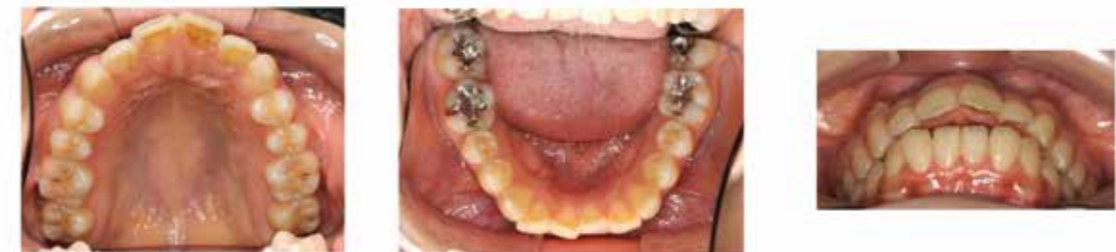

Fig. 36 Pretreatment and prediction tracings: a, pretreatment morphological characteristics; b, treatment objectives

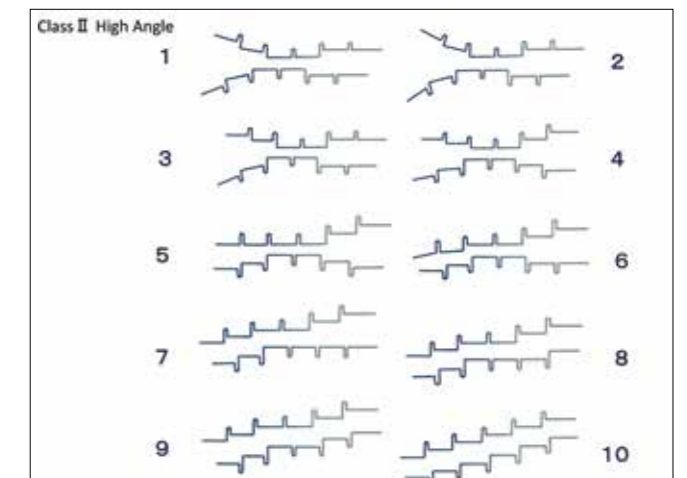
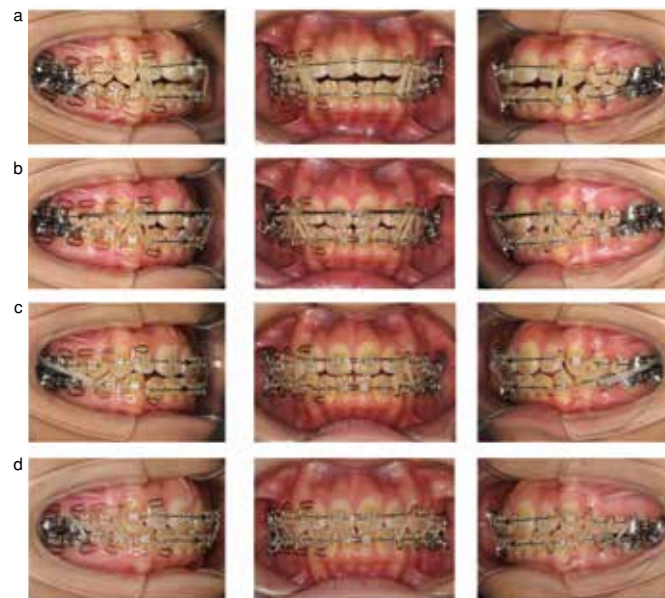

Fig. 37 Sequence of low-vertical Class II open-bite treatment
This malocclusion was associated with an extremely steep occlusal plane, making occlusal reconstruction very difficult. Treatment of this case therefore required flattening of the occlusal plane by increasing the vertical dimension in the mandibular premolar area with step-up bends, intruding and uprighting the mandibular molars, and extruding the maxillary molars to allow forward adaptation of the mandible. Bends were made to accomplish these objectives in Steps 1 through 10.

Her course of treatment and posttreatment photographs are shown in Fig. 38 and Fig. 39.



- a. Two weeks after the start of treatment with 0.016×0.022 inch MEAW appliances in the maxillary and mandibular right quadrants, and 0.016×0.022 inch GEAW appliances in the maxillary and mandibular left quadrants. Step bends were placed in the premolar area from the beginning of treatment. The molars were uprighted and intruded with a series of 20° tip-back bends. Vertical elastics (3/16 inch, 6 oz.) were worn.
- b. At 3 months, the MEAW appliances were kept in place on the right side, while the size of the left GEAW appliances were increased to 0.017×0.022 inch. The tip-back bends were increased by 5° to eliminate interferences. Step bends were added to the anterior areas as well. The maxillary arch was expanded with a 0.7 mm (GUMMETAL) Mulligan's appliance. Vertical elastics and short Class II elastics were used.
- c. At 5 months, all tip-back bends were removed except for the mandibular molar area. Step bends in the maxillary molar area were also removed to initiate occlusal reconstruction. Class II Check elastics (3/16 inch, 6 oz.) were used to induce forward rotation of the mandible.
- d. At 8 months, stepwise bends were increased to tip the occlusal plane down in the back. Bends were made to extrude the mandibular anterior teeth. Vertical-pull box elastics were used in the anterior and posterior areas for tooth axis control and establishment of occlusal guidance.

Fig. 38 Treatment progress

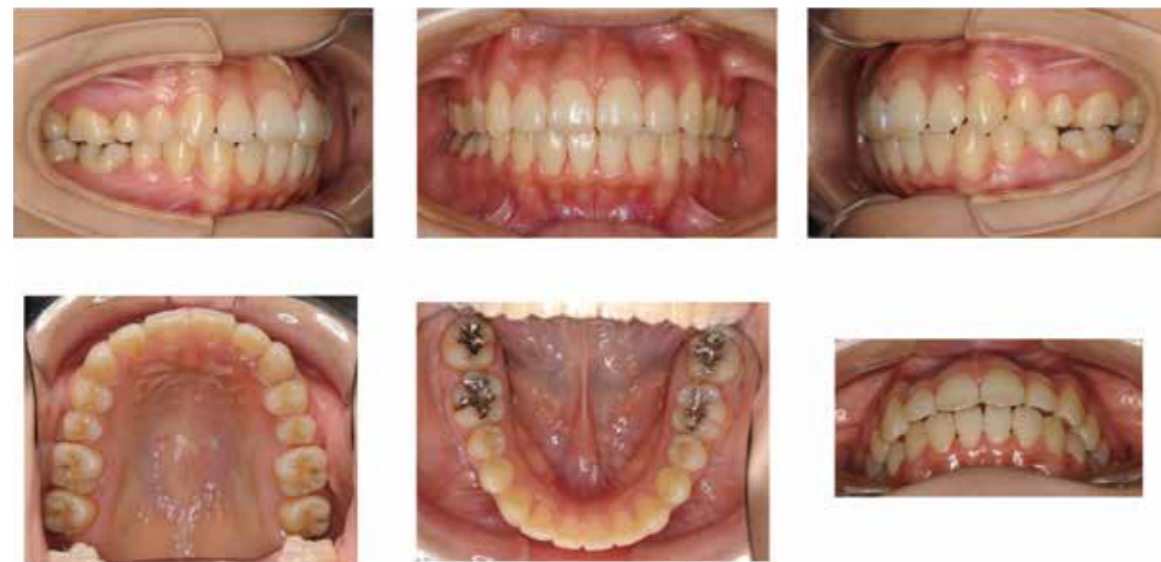

Fig. 39 Posttreatment intraoral photographs
The photographs show Angle Class I canine and molar relationship and improved arch form at the end of treatment.

(4) Sequence of low-vertical Class II deep-bite treatment

An adult female patient presented with maxillary protrusion. Intraorally, the molars were in Angle Class II relationship with an overjet of 8.2 mm and overbite of 4.8 mm. The maxillary left lateral incisor was tipped palatally, and only three incisors were present in the mandibular arch (Fig. 40). The treatment plan for this patient was to flatten the occlusal plane by bringing posterior occlusal plane down through significant vertical increase, so that the mandible would be readapted to a forward position to facilitate compensation in the temporomandibular joints. To achieve these objectives, it was

necessary to determine a physiologic mandibular position, increase the vertical dimension for occlusal support, and establish a proper angle of disclusion in harmony with condylar inclination. Furthermore, appropriate relative anterior guidance and intercoronal opening angle must be established to stabilize mandibular position (Fig. 41). Bends were made to level a deep curve of Spee, a steep posterior occlusal plane, and insufficient vertical dimension; step-down bends in the maxillary premolar area and step-up bends in the mandibular premolar area for increasing the vertical dimension; and step-down bends in the maxillary molar area for flattening the occlusal plane (Fig. 42).

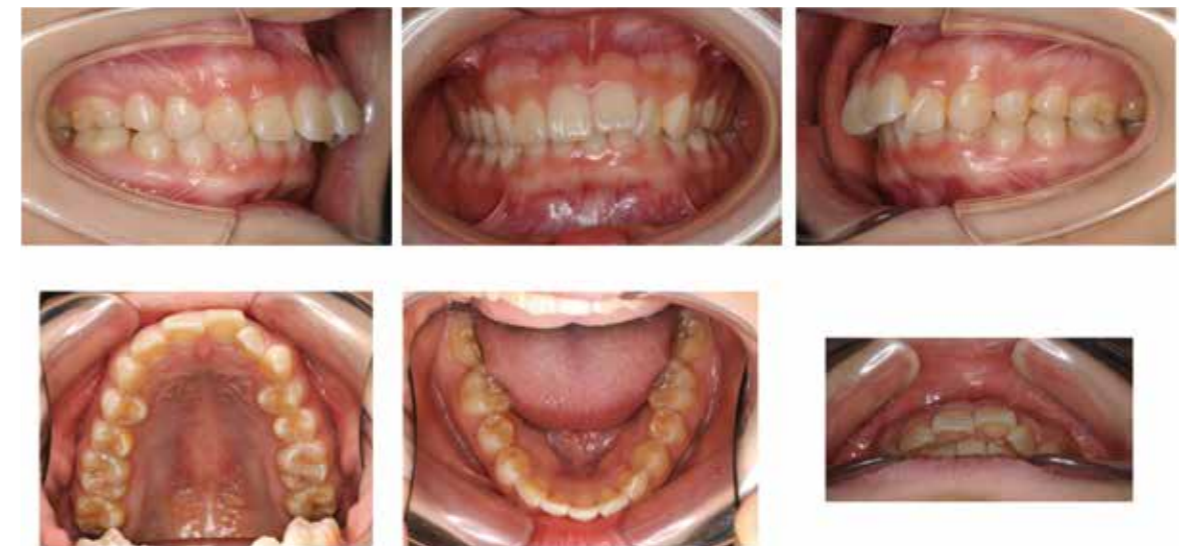

Fig. 40. Initial intraoral photographs of a low-vertical Class II deep-bite case
The canine and molar relationships were Angle Class II with a palatally displaced maxillary left lateral incisor and a missing mandibular incisor.

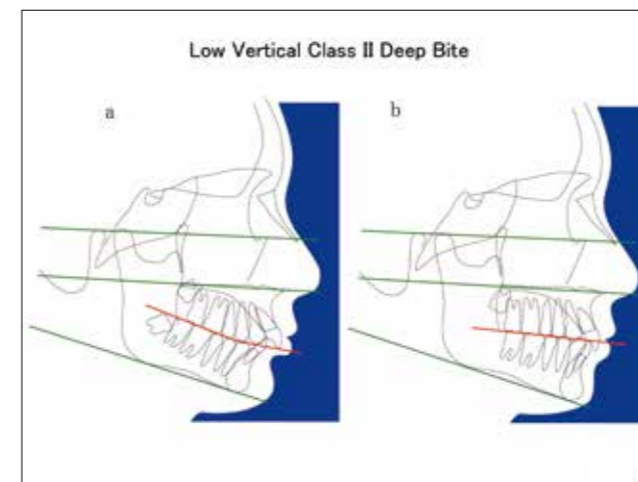


Fig. 41 Pretreatment and prediction tracings: a, pretreatment morphological characteristics; b, treatment objectives

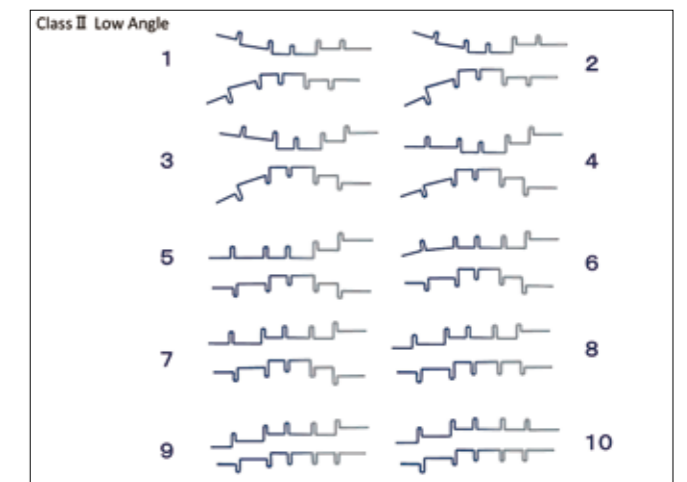
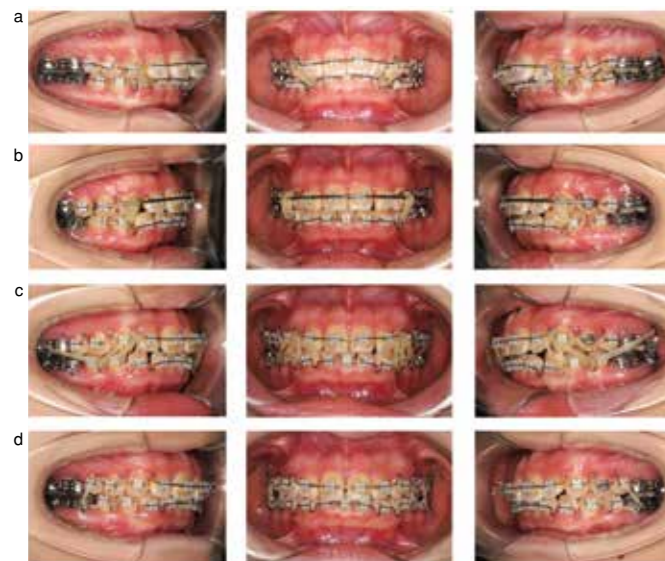

Fig. 42 Sequence of low-vertical Class II deep-bite treatment
The increase of the occlusal vertical dimension failed to keep up with the rate of ramus growth, resulting in the rotation of the posterior part of the mandible and deepening of the curve of Spee. Treatment of this malocclusion called for step-up bends in the premolar area to increase the vertical dimension and flatten the occlusal plane. The sequence of treatment is illustrated in Steps 1 through 10.

Treatment progress (Fig. 43) and posttreatment intraoral photographs (Fig. 44) are shown.



- Two weeks after the start of treatment with 0.016×0.022 inch GEAW appliances with step bends incorporated into the maxillary and mandibular premolar areas from the very beginning. Vertical leveling was initiated with a series of 25° tip-back bends in the molar area. Vertical elastics (3/16 inch, 6 oz.) were attached to Kobayashi hooks.
- At 2 months, the GEAW appliances were increased in size to 0.018×0.022 inch with reinforced tip-back bends for continued uprighting and intrusion of the mandibular molars. Step bends were made in the maxillary and mandibular anterior areas to raise the vertical dimension. Tip-back bends for the maxillary molars were removed, and a 0.7 mm (GUMMETAL) Mulligan's appliance was placed for maxillary arch expansion. Short Class II elastics were attached to Kobayashi hooks mesial to the maxillary and mandibular canines and the mandibular first premolars.
- At 5 months, the anterior occlusal relationship began to improve as the mandibular position was guided forward. The size of the appliances was thus changed to 0.017×0.022 inch. Step bends for the maxillary molars were removed and reverse bends were placed to initiate occlusal plane reconstruction. Vertical elastics and Class II Check elastics (3/16 inch, 6 oz.) were used to start rotating the mandible forward.
- At 9 months, the occlusal plane was flattened further with stepwise bends in the molar area. Step bends in the anterior areas were removed, and box elastics were worn in the premolar area to obtain solid intercuspation.

Fig. 43 Treatment progress

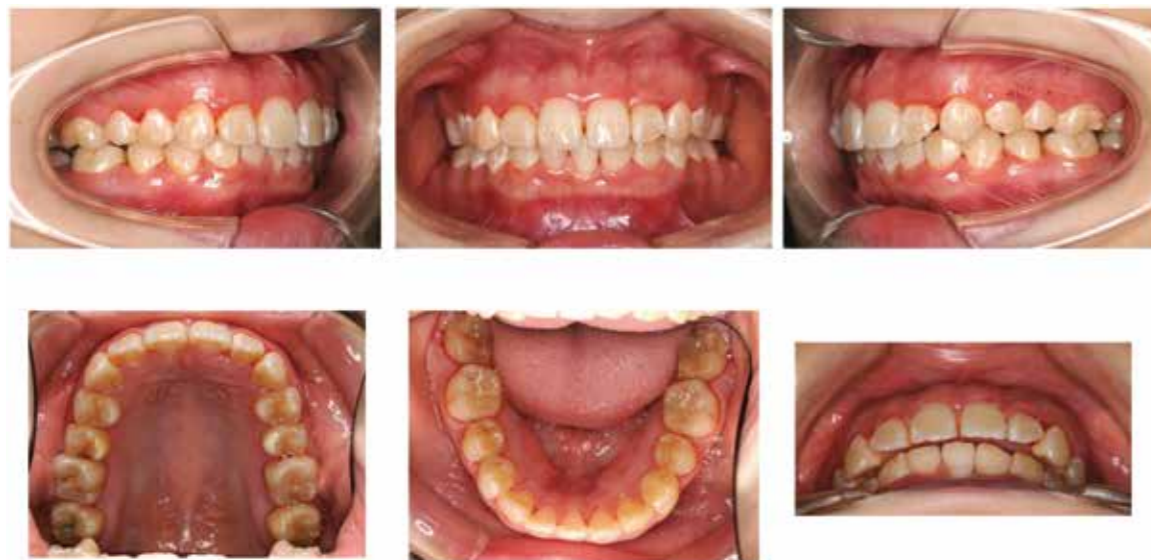

Fig. 44 Posttreatment intraoral photographs
The canine and molar relationships were corrected to Angle Class I, and a normal overjet and overbite was established.

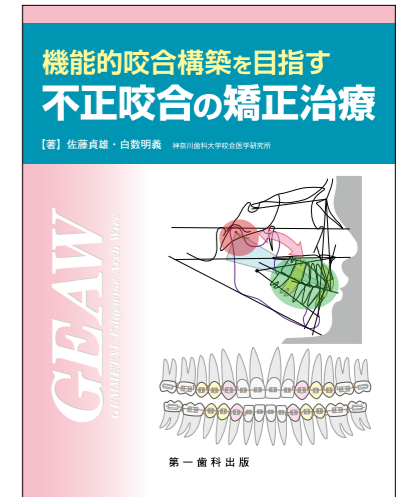Summary

Wire bending exercises are still needed for the GEAW appliance as is the case for the MEAW appliance. However, the use of superelastic and easy-to-bend GUMMETAL wire seems to eliminate major errors in wire bending as long as basic precautions are taken. It is of the utmost importance to have a clear concept of

malocclusion and establish a precise diagnosis (strategy) and a well-defined treatment plan (tactics) in making effective use of the GEAW appliance. Otherwise, the appliance would be of no use. This should to be kept in mind when using this appliance.

< References >

- Shirasu, A., et al.: The concept of malocclusion for the use of the MEAW appliance. Tokyo, Japan: Dental Aspect Vol.21 No.3 Daiichi Shika Publishing; 2007.
- Richardson, E. R. : Atlas of craniofacial growth in Americans of African Descent, Center for Human Growth and Development, Craniofacial Growth Monograph Series, 1991.
- Bhatia, S. N, Leighton, B. C. : A manual of facial growth, A computer analysis of longitudinal cephalometric growth data, Oxford Univ. Press, 1993.
- Sato, S., Sakai, H., Sugishita, T., Matsumoto, A., Kubota, M., Suzuki, Y. : Developmental alteration of the form of denture frame in skeletal Class III malocclusion and its significance in orthodontic diagnosis and treatment. Int J MEAW Tech Res Found 1 : 33-46. 1994.
- Slavicek, R., Sato, S. : The dynamic functional anatomy of craniofacial complex and its relation to the articulation of the dentitions (pp482-514). Das Kauorgan Funktion und Dysfunktionen. Gamma Dental Edition, (Austria) 2001.
- Sato, S.: Dynamics of the maxillofacial skeleton and malocclusion. J Jpn Dent Assoc 1994;47:19-32.
- Sato, S.: What is malocclusion? -Pathogenesis of malocclusion-. Dental Aspect 1999;13:15-16.
- Sato, S.: Maxillofacial vertical dimension and malocclusion -Principles of the body's adaptation and compensation. J Jpn Dent Assoc 2002;55 (3):15-25.
- Sato, S., et al.: Treatment of malocclusion with attention to temporomandibular function. Tokyo, Japan: Tokyo Rinsho Publishing; 1996.
- Sato, S., et al.: Orthodontic treatment using MEAW. Tokyo, Japan: Daiichi Shika Publishing; 2001.
- Sato, S., et al.: Orthodontic treatment using MEAW II [for advanced learning]. Tokyo, Japan: Daiichi Shika Publishing; 2005.
- Shirasu, A., Sato, S.: Orthodontic treatment using MEAW for beginners. Tokyo, Japan: Daiichi Shika Publishing; 2008.
- Shirasu, A., Sato, S.: Orthodontic treatment of malocclusion aimed at reconstructing a functional occlusion. Tokyo, Japan: Daiichi Shika Publishing; 2014.



Curriculum Vitae

Akiyoshi Shirasu D.D.S., Med.Sc.

SHIRASU Dental Office
Visiting teaching faculty: Research Institute of Occlusion Medicine, Kanagawa Dental University

- 1953 Born in Okayama, Japan
- 1978 Graduated from Gifu Dental College (Now Asahi University)
- 1978 ~ 1981 Postgraduate, Department of Oral Surgery, Okayama University
- 1981 ~ 2009 Practice Private Dental Clinic in Okayama
- 1987 Degree of Medical Science, Okayama University
- 2000 ~ 2003 Visiting teaching faculty, Department of Orthodontics, Kanagawa Dental College
- 2003 ~ 2014 Visiting teaching faculty, Department of Craniofacial Growth & Development Dentistry, Kanagawa Dental College
- 2009 ~ Practice Private Dental Clinic and Office (SHIRASU Dental Office) in Okayama
- 2014 ~ Visiting teaching faculty, Research Institute of Occlusion Medicine, Kanagawa Dental University

Sadao Sato D.D.S., D.D.Sc.

Director of Research Institute of Occlusion Medicine, Kanagawa Dental University
Special Professor, Kanagawa Dental University

- 1971 Graduated from Kanagawa Dental College
- 1971 Assistant, Department of Orthodontics, Kanagawa Dental College
- 1979 Assistant Professor, Kanagawa Dental College
- 1979 Degree of Dental Science(D.D.Sc.), Kanagawa Dental College
- 1981 ~ 1982 Visiting research fellow: Prof. W.T.Butler, Department of Biochemistry, University of Alabama
- 1989 Associate Professor, Kanagawa Dental College
- 1991 President, Japanese MEAW technic and Research Foundation
- 1996 Professor, Kanagawa Dental College
- 2001 ~ Visiting Professor, Donau University in Krems, Austria
- 2004 ~ Visiting Professor, Tafts University in Medford, U.S.A.
- 2006 ~ Director, Research Institute of Occlusion Medicine, Kanagawa Dental University
- 2010 ~ 2014 Academic Dean, Kanagawa Dental University
- 2011 ~ 2014 Academic Dean, Shonan Junior College
- 2014 ~ Special Professor, Kanagawa Dental University

Orthodontic Treatment of Malocclusion(Using the GEAW System)



GUMMETAL.
- a wire like no other -

Arch Wire (Ti-Nb)

EN Wire intended for use in orthodontic treatment
 DE Draht zur Verwendung in der kieferorthopädischen Behandlung
 FR Fil destiné à être utilisé dans le traitement orthodontique
 IT Filo destinato ad essere utilizzato nel trattamento ortodontico
 ES Alambre destinado al tratamiento ortodóntico
 PT Fio destinado a ser utilizado em tratamento ortodóntico

JM Ortho Corporation




GUMMETAL.
- a wire like no other -

Straight Wire (rolled)

EN Wire intended for use in orthodontic treatment
 DE Draht zur Verwendung in der kieferorthopädischen Behandlung
 FR Fil destiné à être utilisé dans le traitement orthodontique
 IT Filo destinato ad essere utilizzato nel trattamento ortodontico
 ES Alambre destinado al tratamiento ortodóntico
 PT Fio destinado a ser utilizado em tratamento ortodóntico

JM Ortho Corporation




GUMMETAL.
- a wire like no other -

Straight Wire (Ti-Nb) (cut)

EN Wire intended for use in orthodontic treatment
 DE Draht zur Verwendung in der kieferorthopädischen Behandlung
 FR Fil destiné à être utilisé dans le traitement orthodontique
 IT Filo destinato ad essere utilizzato nel trattamento ortodontico
 ES Alambre destinado al tratamiento ortodóntico
 PT Fio destinado a ser utilizado em tratamento ortodóntico

JM Ortho Corporation



GUMMETAL.
- a wire like no other -

Arch Wire **White**

EN Wire intended for use in orthodontic treatment
 DE Draht zur Verwendung in der kieferorthopädischen Behandlung
 FR Fil destiné à être utilisé dans le traitement orthodontique
 IT Filo destinato ad essere utilizzato nel trattamento ortodontico
 ES Alambre destinado al tratamiento ortodóntico
 PT Fio destinado a ser utilizado em tratamento ortodóntico

JM Ortho Corporation



GUMMETAL.
- a wire like no other -

Straight Wire **White (rolled)**

EN Wire intended for use in orthodontic treatment
 DE Draht zur Verwendung in der kieferorthopädischen Behandlung
 FR Fil destiné à être utilisé dans le traitement orthodontique
 IT Filo destinato ad essere utilizzato nel trattamento ortodontico
 ES Alambre destinado al tratamiento ortodóntico
 PT Fio destinado a ser utilizado em tratamento ortodóntico

JM Ortho Corporation

